

# Ulnar Sided Wrist Pain

The term “wrist” is used to describe the joint where the hand is connected to the forearm. The actual anatomy of the wrist is not as simple. There are eight smaller bones that connect the five main hand bones (metacarpals) to the two forearm bones (radius and ulna) **(Figure 1)**. Pain on the pinkie (ulnar) side of the wrist is very common. It can result from injury to bones, cartilage, ligaments or tendons.

## Causes

Due to the many parts in this “pinkie” side of the wrist, determining the cause of ulnar-sided wrist pain can be very difficult. Your hand doctor will examine your wrist to see where the pain is located and how the wrist moves. X-rays might be taken. Sometimes other studies such as a CT scan or MRI might be needed.

Some causes of ulnar-sided wrist pain include:

- Wrist fractures
- Arthritis of the joint(s) between bones
- Ulnar impaction syndrome (when the ulna is longer than the radius, which can cause it to “bump into” the smaller wrist bones **(Figure 2)**)
- Inflammation or irritation of the tendons that bend and extend the wrist
- Triangular Fibrocartilage Complex Injury (TFCC) (when the connection between the ulna bone and other structures in the wrist is torn by an injury or frayed over time)
- Nerve injury or compression
- Masses (tumors), most commonly ganglion cysts, which are benign

## Signs and Symptoms

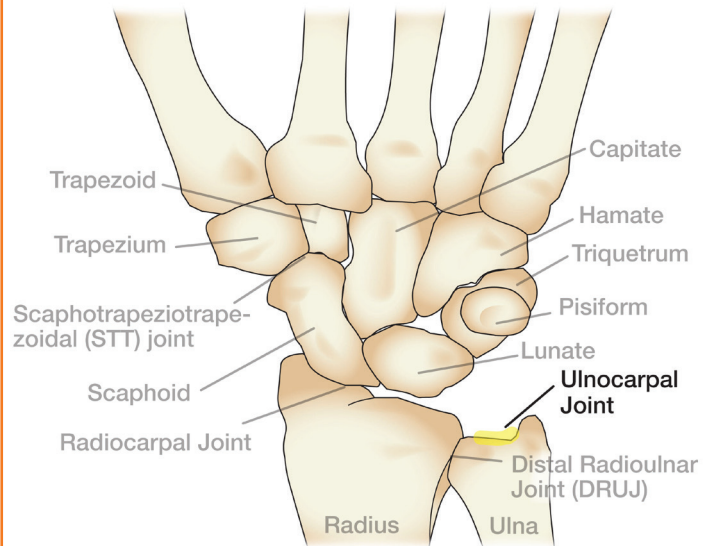
Pain can be felt at rest or with motion. Symptoms can include:

- Pain on “pinkie” side of wrist with movement
- Clicking or popping, especially with rotation
- Decreased grip strength
- Decreased or limited motion

## Treatment

The treatment of ulnar-sided wrist pain depends on the diagnosis. It can include some combination of activity modification, splinting or casting, hand therapy, anti-inflammatory medicine and/or steroid injections. If non-operative treatment does not relieve symptoms, surgery might be considered.

**Figure 1:** Wrist bones and joint



**Figure 2:** Ulnar impaction, an ulna longer than the radius

